



PATIENT

Rosie Lachance

SPECIES

Canine

BREED

Jack Russell Terrier

SEX

Female Spayed

AGE

10 years

WEIGHT

18.5lbs

PRESENTING CLINICAL SIGNS

History: History of chronic tracheal cough that has been getting progressively worse, and mildly decreased activity. Has a grade III/VI murmur. Echo prior to anesthesia for dental procedure. BP: 164, 165, 167mmHg

ECHOCARDIOGRAM FINDINGS

2D, m-mode, color flow and Doppler imaging is available.

Left ventricle: The LV diameter is normal with adequate myocardial function. LV wall thicknesses are normal.

Left atrium: The left atrium is mildly dilated.

Mitral valve: The mitral valve is diffusely thickened with mild prolapse into the left atrial lumen. Mild eccentric mitral regurgitation with a normal velocity.

Aortic valve/aorta: The aortic valve is normal in morphology and mobility. Normal aortic outflow velocity; laminar flow. No aortic insufficiency.

Right ventricle: Normal right ventricular diameter and morphology indicating no overt evidence of pulmonary arterial hypertension.

Right atrium: Normal RA dimension.

Tricuspid valve: The tricuspid valve appears normal with mild tricuspid regurgitation; normal velocity.

Pulmonic valve/pulmonary artery: The pulmonic valve is normal in morphology and mobility. No pulmonic insufficiency. Normal RVOT velocity; laminar flow.

Pericardium/other: No pericardial or pleural effusion noted. No obvious cardiac masses.
Heart rhythm: ECG reveals a sinus rhythm with an average HR of 100bpm.

INTERPRETED BY

Maggie Machen
Lamy, DVM
DACVIM (Cardiology)

2-Dimensional Measurements

Ao diam (cm)	1.5
LA diam (cm)	1.8
LA:Ao (Swe)	1.2
IVS thickness (cm)	0.7
LVID diastole (cm)	2.6
PW thickness (cm)	0.7
LVID systole (cm)	1.1
FS (%)	56

Doppler Measurements

PV Vmax (m/s)	0.75
AoV Vmax (m/s)	1.1
MR Vmax (m/s)	5.5
TR Vmax (m/s)	2.7
TR PG (mmHg)	30

IMAGING

PERFORMED BY

Pamela Harrigan,
RDCS

INTERPRETATION OF THE FINDINGS

The cause of the murmur is chronic degenerative valve disease causing mild mitral and tricuspid regurgitation. Lack of significant left atrial enlargement indicates the current risk for complication is low. No concurrent issues such as systolic dysfunction or pulmonary hypertension are noted in this study.

HOSPITAL NAME

Compassionate Care
Veterinary Clinic

REFERRING VET

Dr. Farrington

Given these findings, the cough is unlikely to be cardiac in origin and primary respiratory causes should be considered. Consider further respiratory work up/treatment (hydrocodone, taper course of steroids, Enrofloxacin, TTW/BAL, etc.).

INVOICE

27038

Assessment of progression in the future will help predict long term prognosis, which is highly variable at this stage (B1).

DATE

10/21/22



PATIENT

Rosie Lachance

SPECIES

Canine

BREED

Jack Russell Terrier

SEX

Female Spayed

AGE

10 years

WEIGHT

18.5lbs

INTERPRETED BY

Maggie Machen
 Lamy, DVM
 DACVIM (Cardiology)

IMAGING PERFORMED BY

Pamela Harrigan,
 RDCS

HOSPITAL NAME

Compassionate Care
 Veterinary Clinic

REFERRING VET

Dr. Farrington

INVOICE

27038

DATE

10/21/22

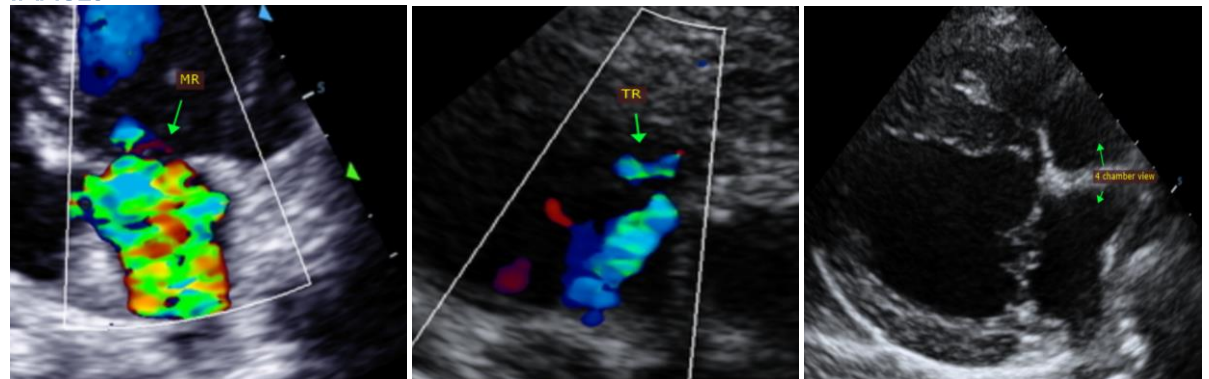
RECOMMENDATIONS

- In a dog without significant left atrial enlargement, no cardiac medications are clearly indicated.
- Omega fatty acid supplementation and mild salt restriction may be of some long-term benefit.
- Anesthetic risk is considered mild if needed. Cardiac protective drug choices (opioid/benzodiazepine premedication, propofol or alfaxalone induction, isoflurane gas) are recommended. Pre-oxygenate for 5-10 minutes prior to induction. Monitor for arrhythmias, hypotension, and hypoxia both intra and post-operatively and intervene as necessary. Mild IV fluid restriction is recommended to avoid fluid overload. Avoid heart rate stimulating drugs such as atropine unless clinically indicated.
- Monitor for development of a cough, labored breathing, exercise intolerance or collapse episodes.

PLAN

- Recommend conservative monitoring with a recheck echocardiogram in 6 months, sooner if any development of clinical signs.

IMAGES



The information and recommendations provided are based on the images presented by the referring veterinarian. No evaluation can be communicated regarding pathology that was not visible in the image/video clips provided.

Thank you for this referral. This report was generated using transcription software, and minor dictation errors may be present. If the clinical or image interpretation does not parallel your findings or if I can be of any further assistance, please contact me.

Maggie Machen Lamy, DVM
 Diplomate of the American College of Veterinary Internal Medicine (Cardiology)
 info@sonopath.com